

Repair of Unstable Chest Wall Utilizing Zip Ties

Daniel Akyeamong, MD; Evert A. Eriksson MD, FACS, FCCP, FCCM
The Medical University of South Carolina

Patient

- 50 y/o Male
- Forklift accident
- Respiratory failure 2/2 to flail chest

Injuries

- Costal margin rupture of the left chest with a traumatic thoracotomy and lung herniation
- Flail chest of left ribs 6, 7, and 8
- Displaced fractures of left posterior ribs 4 and 5

Repair

- Open reduction-internal fixation performed on ribs 4, 5, 6, 7, 8 with supportive cross-plating and suspension zip ties to aid in support of the chest wall rebuilding in the costal margin
 - A rib resection partial was performed on the 8th rib to remove a devitalized tip of the 8th rib.
- A chest tube was placed through a separate incision

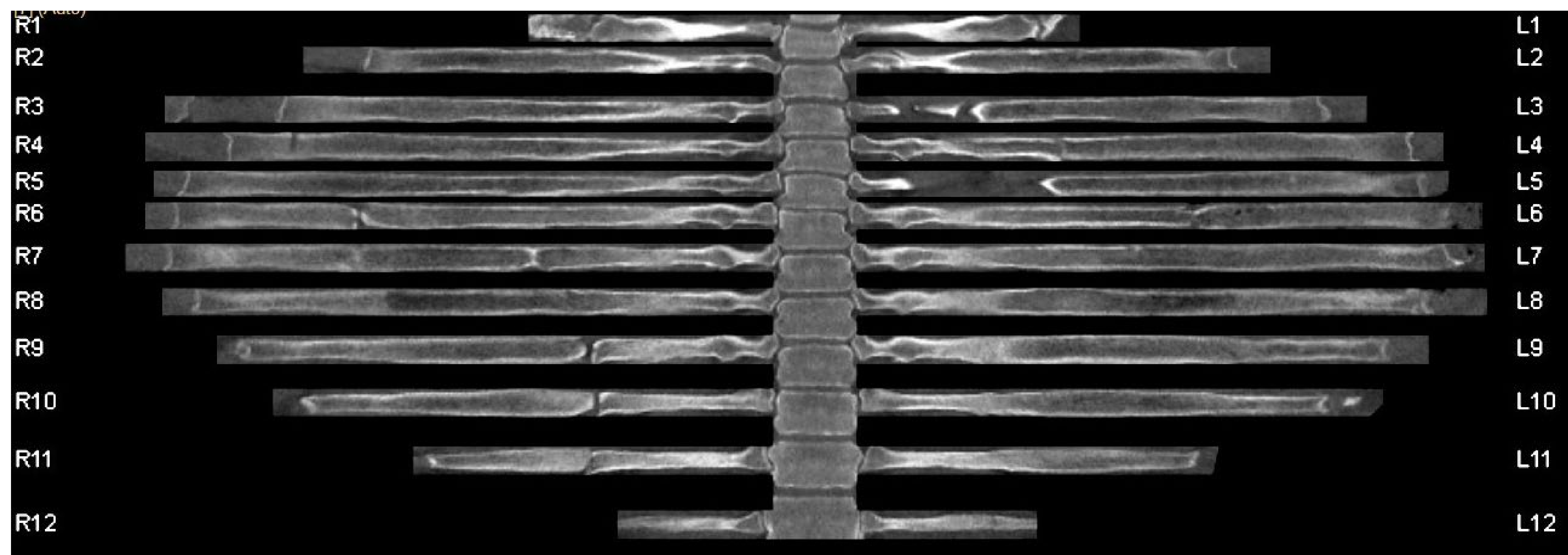


Figure 1.

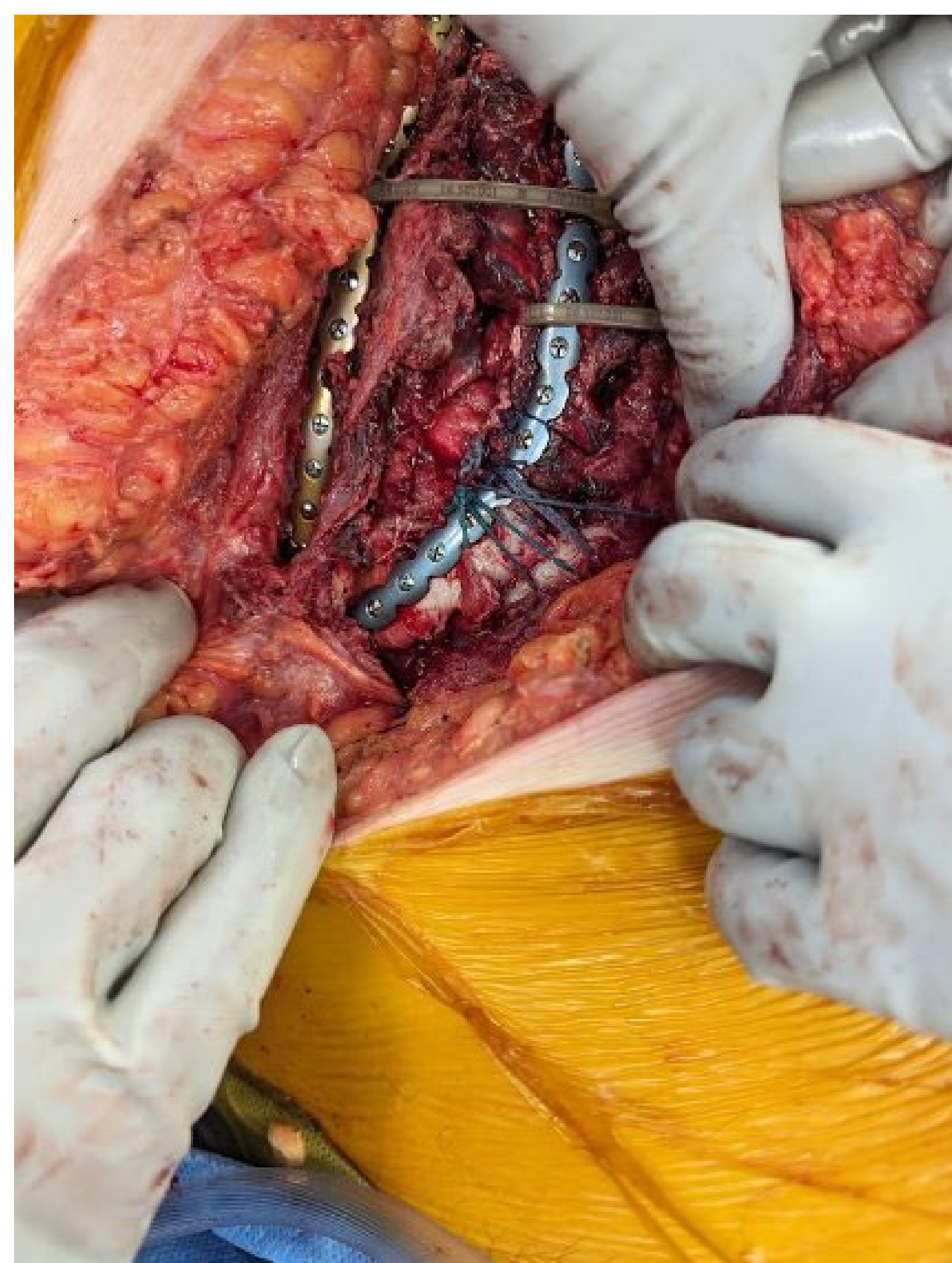


Figure 2.

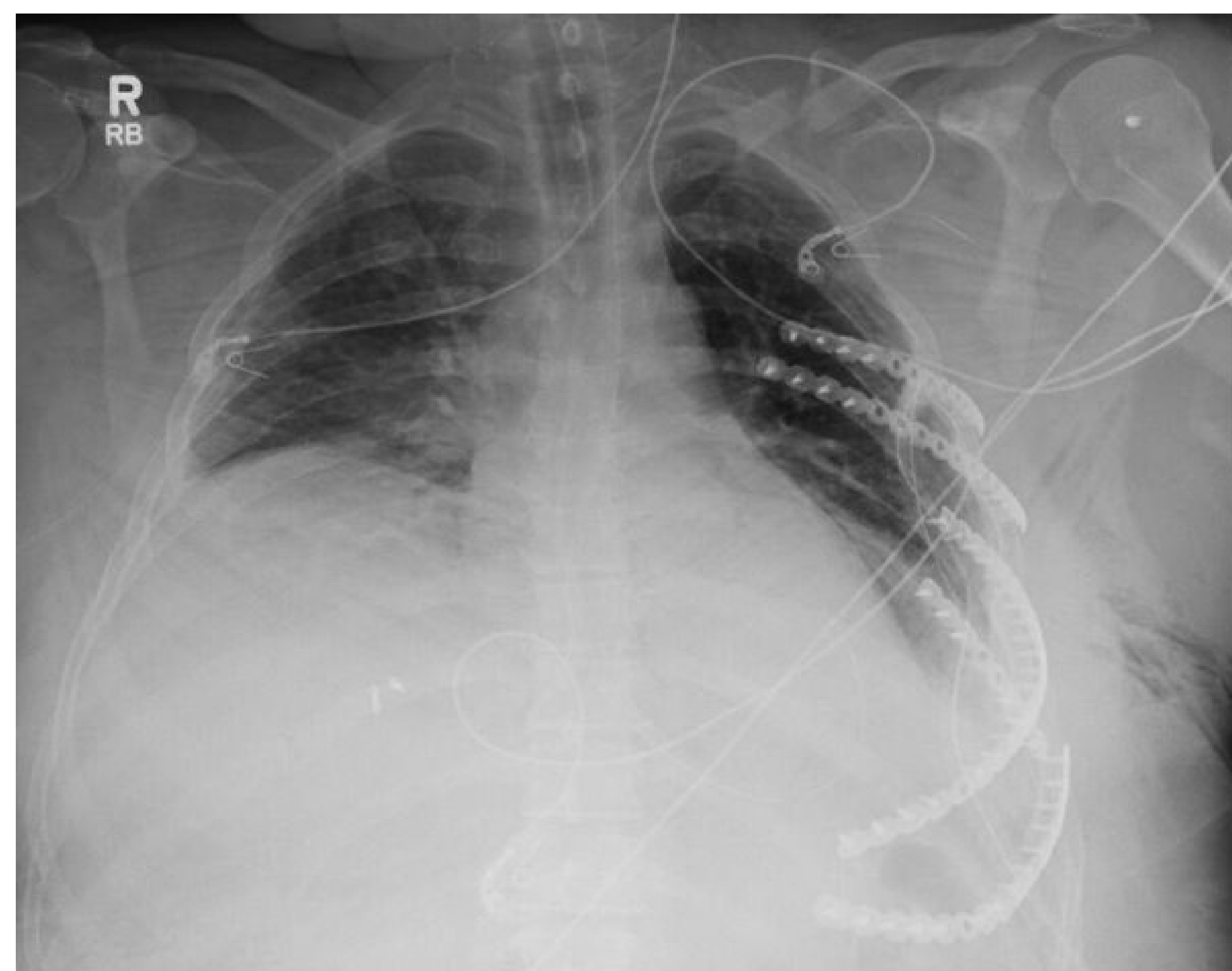

Figure 3.

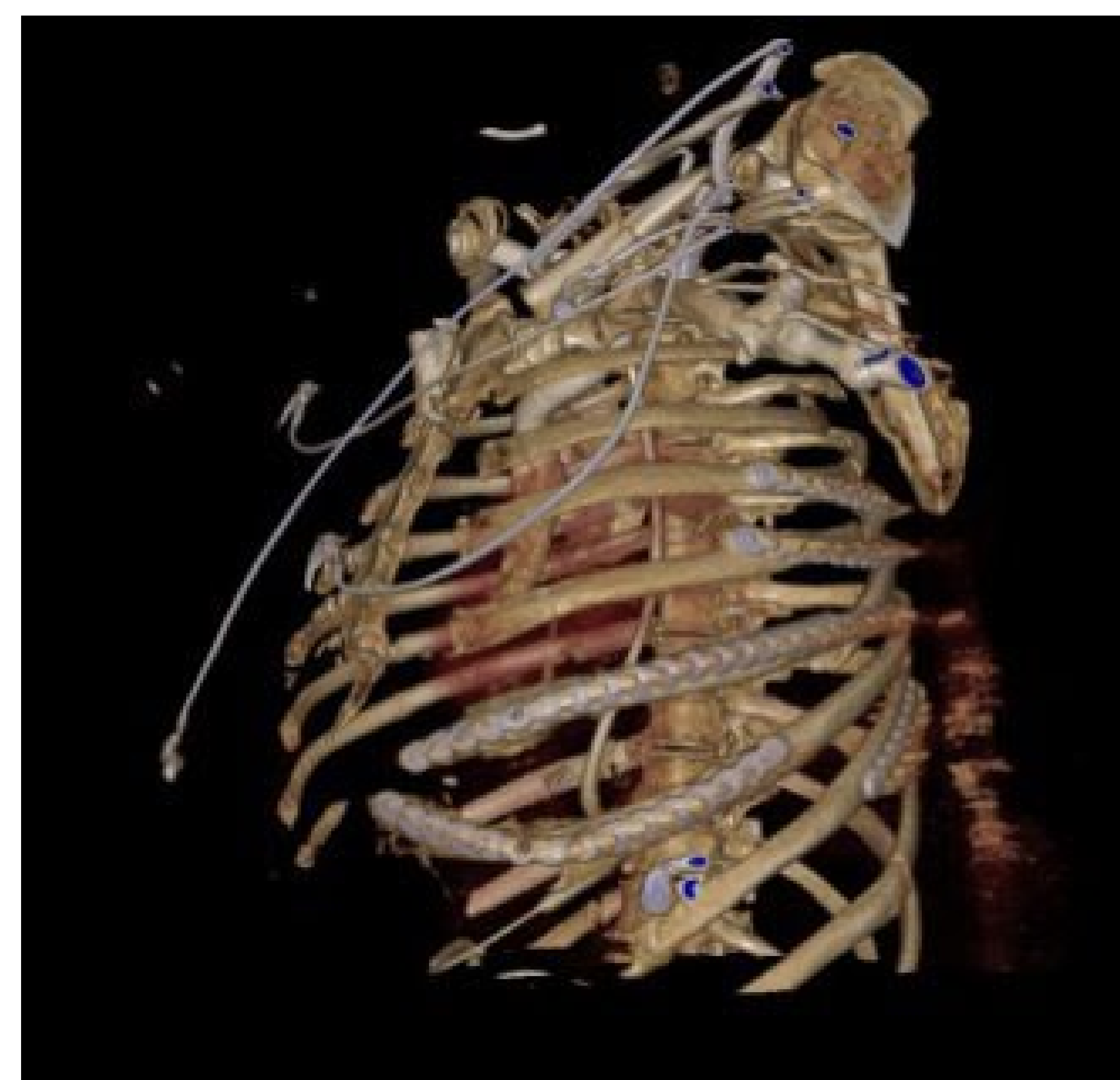


Figure 4.

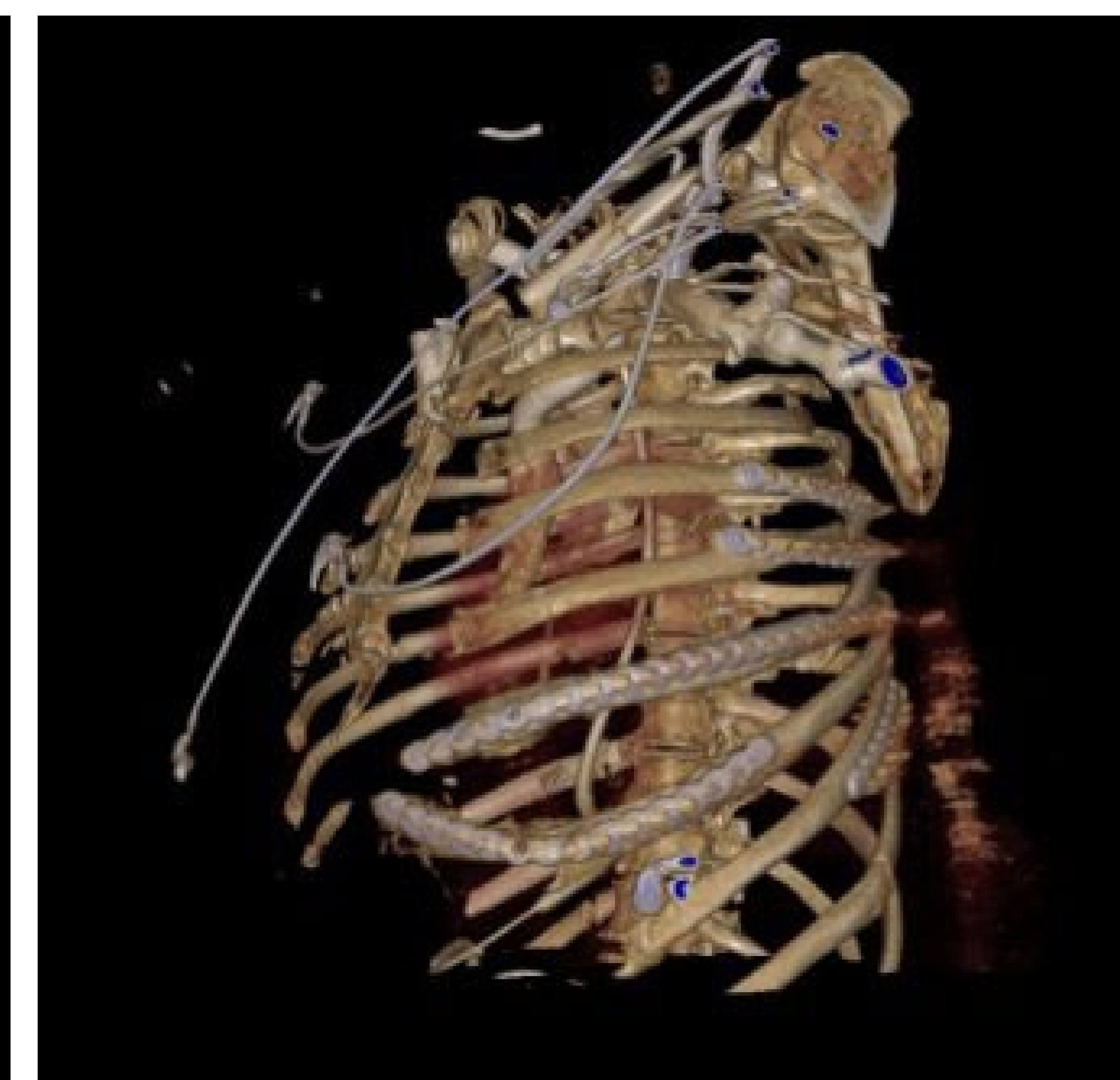


Figure 5.