

“Shots Fired- Ribs Wired”- Two cases of Rib Fixation with Gun Shot Wounds

Hason Khan, Sydney Todd, Samuel Cemaj, Zachary Bauman

Background

Rib fractures are known to be one of the most common injuries following blunt trauma, however, they can also be associated with penetrating trauma. Penetrating thoracic injuries can result in devastating trauma to multiple organ systems. Prompt diagnosis and swift treatment of internal organ injuries are of utmost importance for these patients. Here, we present two cases of patients who were admitted to the hospital with gunshot wounds and concomitant rib fractures.

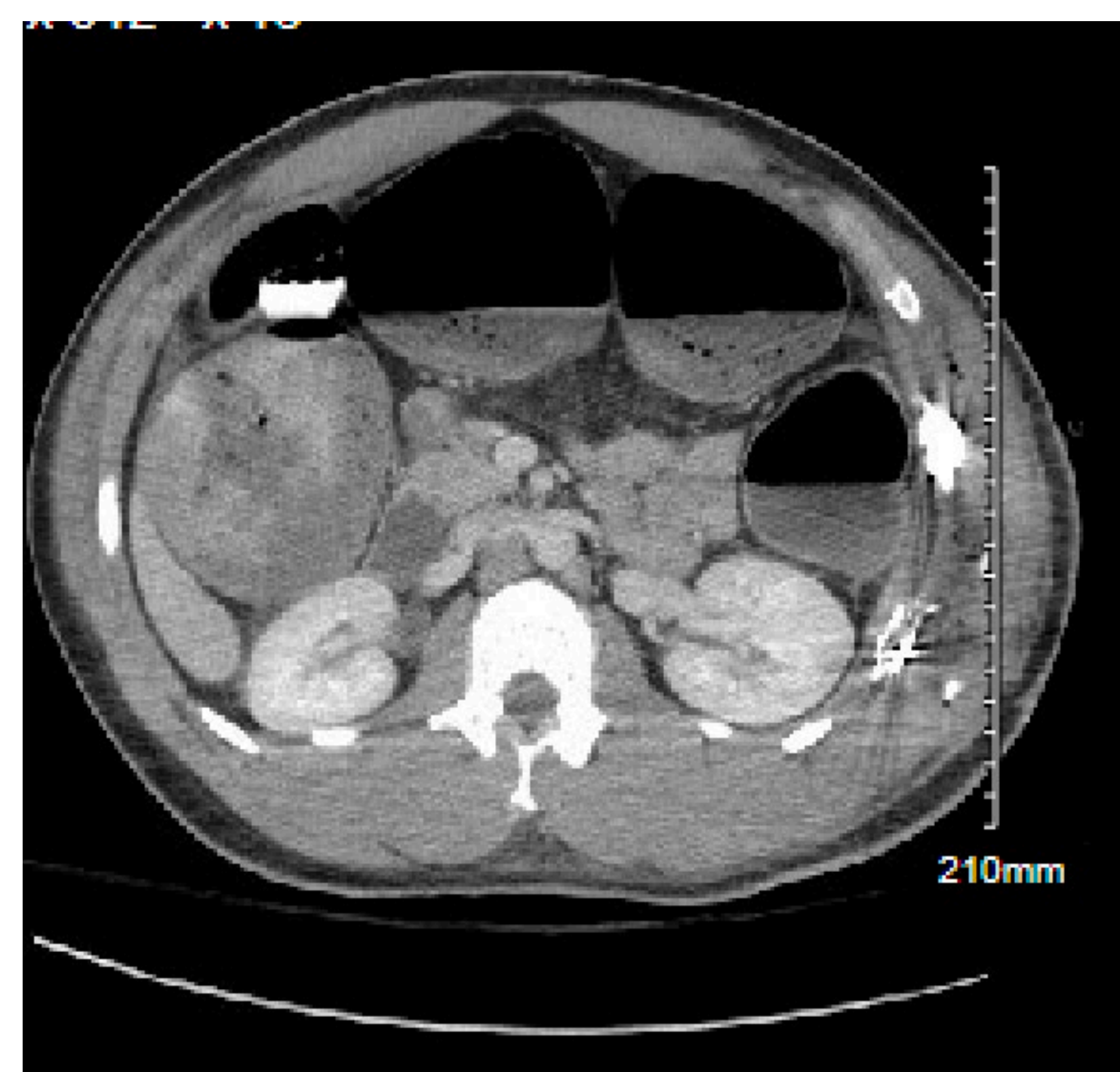
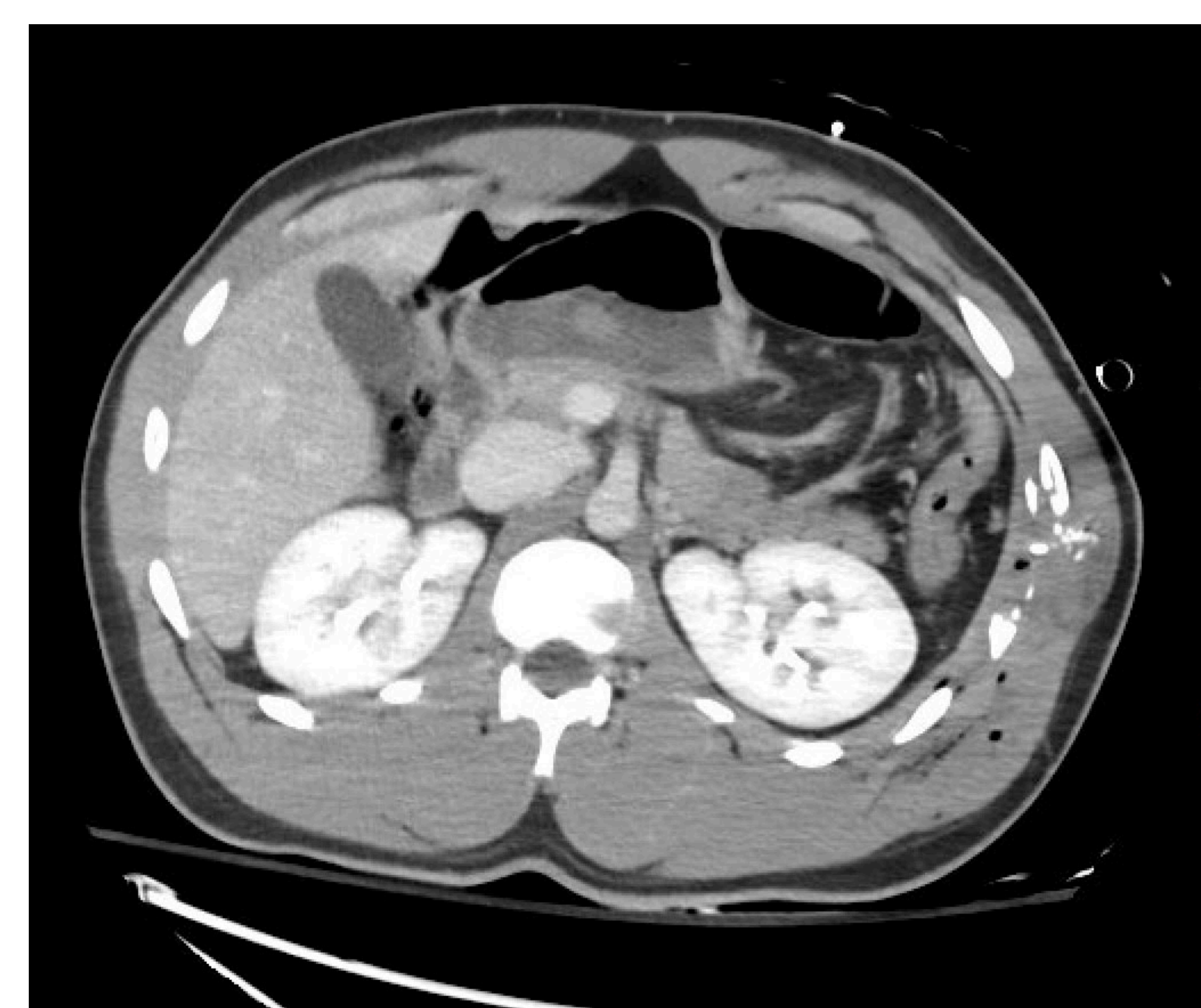
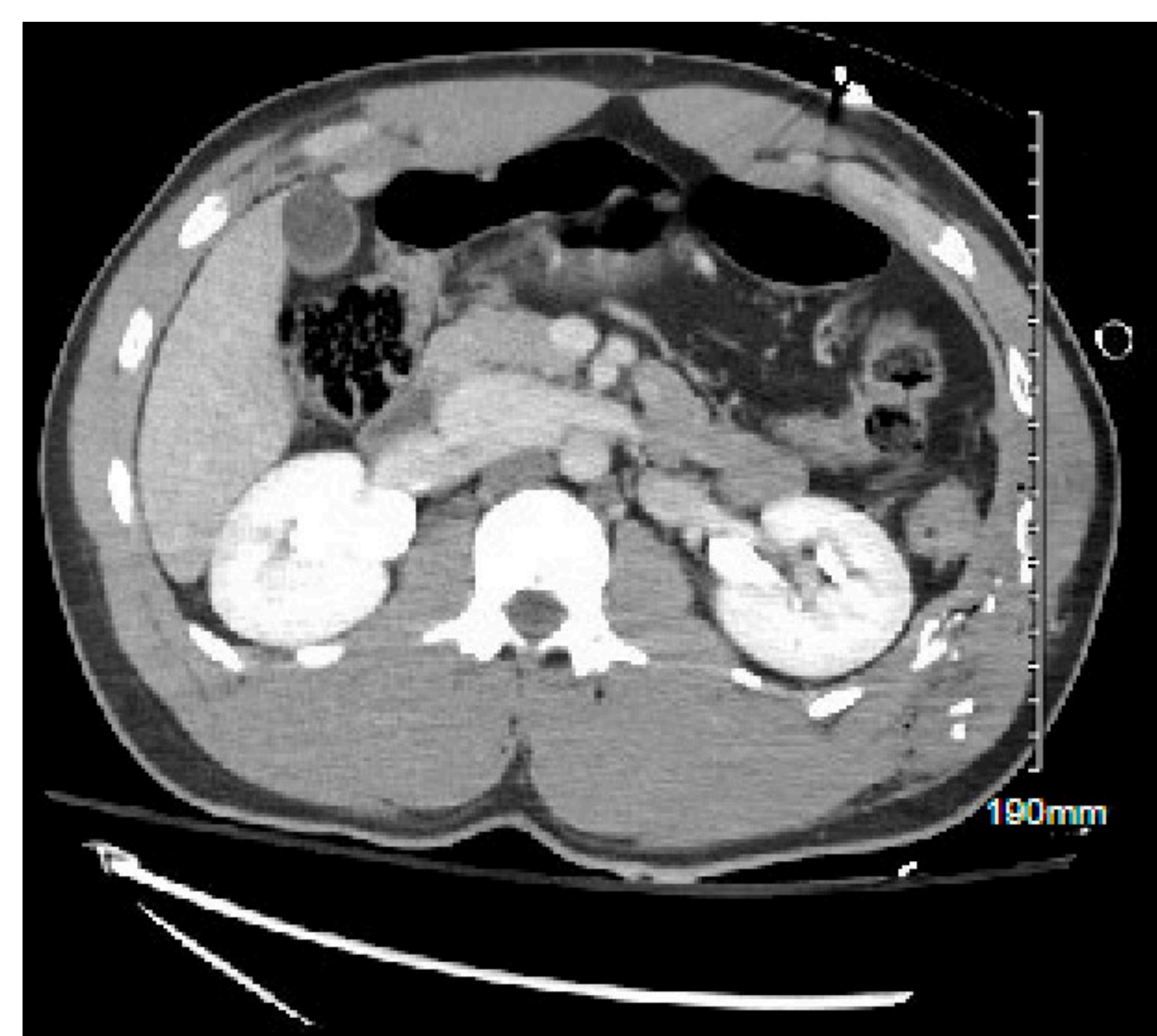
Case Presentations

Case 1: We report on a 27-year-old male patient who was admitted to the hospital with gunshot wounds to the left thorax and left arm. Patient was found to have hemopneumothorax as well as shattered ribs two, five, and six. The patient presented in respiratory distress with breath sounds diminished bilaterally.

Case 2: We report on a 26-year-old male patient who presented with multiple gunshot wounds to the rectum, scrotum, left pubic symphysis fracture, and pneumothorax. The bullet did not enter his chest cavity, however it destroyed ribs 8-10.

Case 1

Ribs five and six were quite unstable with significant bone loss, thus it was determined a left wall reconstruction was needed. An intrathoracic plate and extrathoracic plate was used to fix and stabilize rib fractures five and six with the Zimmer-Biomet intrathoracic plating system. The plates were positioned on the intrathoracic side of the ribs to appropriately align the fractures. Due to significant damage to intercostal muscles and bone loss, an additional thoracic plate was inserted between the two intrathoracic plates. Blue system plates were employed to bridge the fractures from an extra thoracic approach and demineralized bone matrix (DBM) was used for healing promotion. Both rib fracture repairs were reinforced with intra and extra thoracic plates along with DBM. Cryoablation of intercostal nerves four through seven was performed on the patient.



Case 2

A intrathoracic plate was placed on ribs 8 and 9 given the amount of bone loss. Plates were placed against the internal surface, and extrathoracic plates were used to span the fractures using the sandwich technique. DBM was placed again to promote bone healing. An extra thoracic plate was placed on rib 10 with 8 mm titanium screws being placed on either side of the rib fracture. Cryoablation of ribs was performed from ribs 5 to 9 and intercostal nerve block of nerves 6 through 9 was also used. 2 weeks later the patient presented to clinic with diminished pain and no complaints of popping, clicking, or movement of ribs.

