

CWIS Summit
Atlanta, Georgia
April 23-26, 2025

^{1,2}Jessica L. Xu, MS MD; ^{1,2}Alejandra Huaco, MD; ^{1,2}Jeff Winters, DPT; ^{1,2}Peter A. Cole, MD

¹Department of Orthopaedic Surgery, Regions Hospital, St. Paul, MN, United States
²Department of Orthopaedic Surgery, University of Minnesota, Minneapolis, MN, United States

Disclosures:
No funding was received for this study

Introduction

- General principle of orthopaedic fracture – obtain orthogonal X-ray (XR)
- However, there are no guidelines for postoperative imaging in patients who undergo surgical stabilization of rib fractures (SSRF)¹
- Rib nonunion and malunion can result in chronic pain and debilitation^{2,3,4}
- Purpose: determine pathology which may be missed with the standard chest XR (CXR) compared to oblique rib XRs

Methods

Inclusion: Patients from 2017-2024 who underwent rib open reduction and internal fixation (ORIF) or reconstruction

Exclusion: No complete set of XRs at minimum two months follow-up

Primary Outcome: Bone healing (callus, bone bridging) and hardware failure (plate pull out, plate breakage, or screw pull out and breakage)

Secondary Outcome: mm displacement in hardware failure

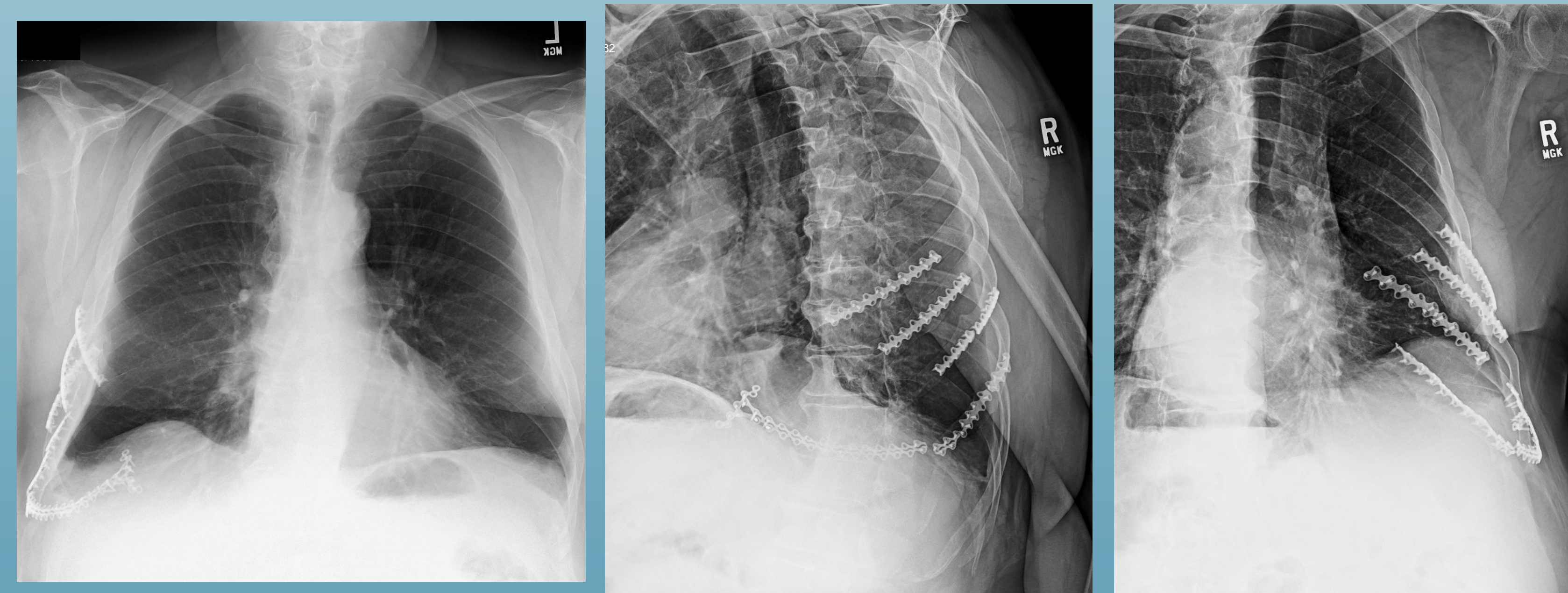
Results

Primary Outcomes

- Forty-two patients with a total of 142 fixed ribs
- Average time between surgery and CXR and Rib Series: 8.1 months
- Hardware complications were identified equally in CXR and oblique XRs (n=6)
- Healing was identified 23% more in oblique XRs than CXR (n=114 (80%) vs 81 (57%))
 - In 61 ribs where healing was not certain in CXR, 36 showed signs of healing on oblique XRs

Secondary Outcomes

- Compared to CXR, oblique XRs characterized an average difference of 3.3 mm more displacement in fracture distraction and 6.47 mm more displacement in plate failure (14.2 vs 7.8 mm)

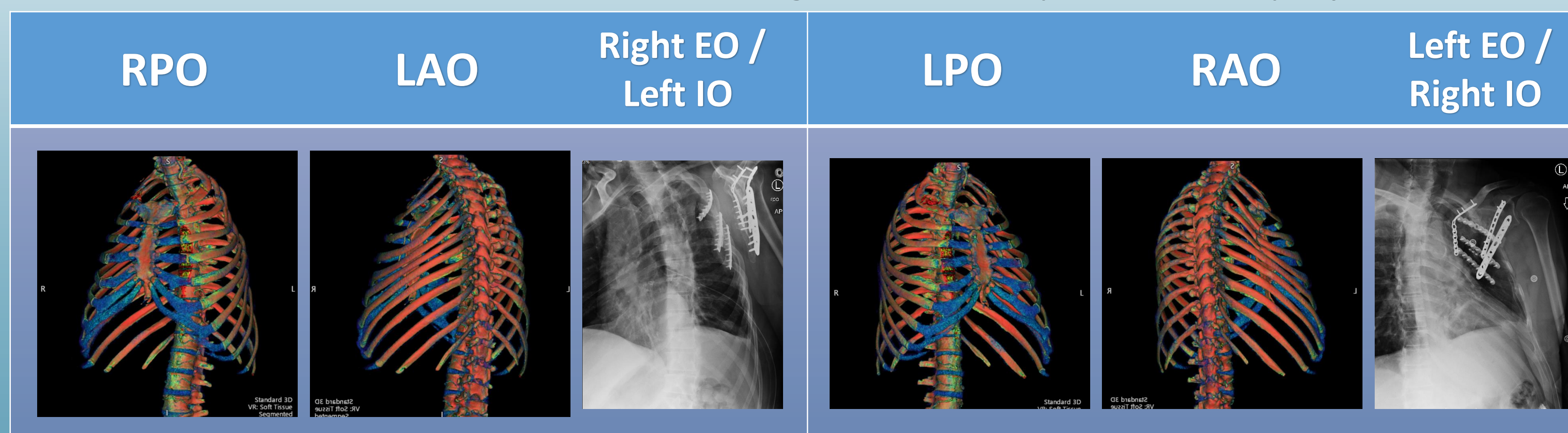


Discussion

- Oblique XR views showed additional findings of healing and displacement than CXR alone
- Hardware complications were found equally
- Ribs are elongated and isolated in oblique XR views which allows for more comprehensive characterization.
- Rib series technique should be reviewed with radiology technicians for quality control
- SSRF or reconstruction patients should receive oblique radiographic views at follow-up to appropriately assess healing and complications.

Tips and Tricks for Oblique Rib Series

- For bone films, take XR at lower kV and higher mA for optimal bone projection



Scan for more examples



References

1. Zhang L, McMahon CJ, Shah S, Wu JS, Eisenberg RL, Kung JW. Clinical and Radiologic Predictive Factors of Rib Fractures in Outpatients With Chest Pain. *Curr Probl Diagn Radiol.* 2018;47(2):94-97. doi:10.1067/j.cpradiol.2017.05.011
2. Cole PA. Rib and Sternum Nonunions: Diagnosis and Treatment and Awareness of Other Potential Posttraumatic Pathology. *J Orthop Trauma.* 2024;38(12S):S33-S40. doi:10.1097/BOT.0000000000002922
3. Ogunleye TD, Carlson DA, Thomas CN, Schroder LK, Cole PA. Outcomes After Operative Reconstruction of Symptomatic Rib Nonunions. *J Orthop Trauma.* 2022;36(5):e161-e166. doi:10.1097/BOT.0000000000002275
4. Gauger EM, Hill BW, Lafferty PM, Cole PA. Outcomes after operative management of symptomatic rib nonunion. *J Orthop Trauma.* 2015;29(6):283-289. doi:10.1097/BOT.0000000000000254